

Evaluation of Different Drugs for Prevention of Dry Socket after Extraction of Lower Wisdom Teeth

Adil O. Abdullah BDS, HDD⁽¹⁾

Ibrahim S. Gataa BDS, FICMS⁽²⁾

Falah A. Hawramy BDS, HDD, FICMS⁽³⁾

Key words

dry socket, acute alveolar osteitis, amoxicillin, chlorhexidine

Abstract

Dry socket is one of the most common complications of tooth extraction especially after lower wisdom tooth removal. Many drugs have been used to decrease the incidence of this complication. The purpose of this study was to evaluate different drugs in prevention of dry socket. In this study 150 patients needs removal of lower wisdom tooth were included. The patients divided into five equal groups were and each group received different type of drug postoperatively. The patients were evaluated for the presence of dry socket in the 2nd, 5th, and 7th day after tooth extraction. The females were affected more than males in this study with 2.1: 1 ratio. The incidence of dry socket in the total number of the patients was 17.3%. The analysis of the data showed no significant relations between the five groups as the P value was > 0.05. The use of different drugs postoperative in this study showed no differences in the incidence of dry socket which high lighten the use of preventive measures to decrease the occurrences of such condition.

Introduction

Dry socket is one of the most common complications of tooth extraction characterized by severe pain starting usually on the second or third day postoperatively. Its prevalence has been reported to be varied and it may reach more than 35%⁽¹⁾. It is more common following mandibular third molar extraction which is the most common procedure done in the oral cavity. The exact pathogenesis of dry socket is not well understood. However, disintegration of the blood clot by fibrinolysis remains the most widely accepted theory⁽²⁾. Several contributing factors have been reported to be associated with an increased risk of dry socket. They include traumatic extraction, preoperative infection,

smoking, sex, site of extraction, use of oral contraceptives, use of local anesthetics with vasoconstrictors, inadequate postoperative irrigation and low level of operator experience. Several methods have been advocated to reduce the incidence of dry socket including the use of antiseptic mouthwashes, antifibrinolytic agents, antibiotics, steroids, clot supporting agents, and other intra-alveolar dressings⁽³⁻⁷⁾. While the exact aetiology of this condition cannot be completely established, its management appears to be simple and effective. It usually involves reassurance of the patient, cleaning and irrigation of the affected socket, and insertion of a medicated. In this study we used different types of drugs in prevention of dry socket to compare the effect of each type according to the incidence of the condition.

(1) Senior in Oral Surgery Department, Khanzad Dental Polyclinic, Erbil General Directorate of Health, Erbil, Iraq

(2) Assist. Prof., Department of Oral Surgery, College of Dentistry, University of Sulaiman

(3) Lecturer, Department of Oral Surgery, College of Dentistry, University of Sulaiman

Material and Methods

In this clinical comparative study the patients were divided into five groups. Each group received different treatment after extraction of lower 8 as following:

Group A: Use only salt-water mouth rinse (Thirty cases).

Group B: Use only chlorhexidine 0.01% mouth rinse(Thirty cases).

Group C: Use antibiotics only for five days (Thirty cases) including:

- 1-Amoxicillin (500 mg) three times daily.
- 2-Mertnidazole (400 mg) three times daily.

Group D:Use salt-water mouth rise with antibiotic as group C(Thirty cases).

Group E: Use chlorhexidine 0.01% mouth rinse with antibiotic as group C (Thirty cases).

Sample Collection

Data collected from the patients attending the Peremerd Dental Center for extraction of lower wisdom teeth. After the extraction the patients will be treating by different drugs as above.

Surgical procedure

- 1-The patient evaluated clinically and radiographically.
- 2-All the patients treated by the same operator in the same place.
- 3-The patients received paracetamol tablets (1000mg) one hour after tooth extraction and three doses of 500mg in the day after tooth extraction .
- 4- The patient followed for the 2nd,5th and 7th days after extraction.

Patients were diagnosed with a dry socket if they had either one or both the following signs and symptoms:

- a. Empty socket with or without food debris
- b. Pain in or around the socket occurring within one week of the extraction

Inclusive Criteria

- 1-Erupted vertical mandibular 3rd molars that needed extraction.
- 2-Non surgical extraction.
- 3-Age: 18 – 25 years.
- 4-No allergies to local anesthetic agents.
- 5-No allergies to Amoxicillin and Metronidazole.
- 6-The study patient has been approved by ethical form.

Exclusion Criteria

- 1-History of systemic diseases.
- 2-Recent medication (within 2 weeks).
- 3-Pregnant or lactating women, women who use oral contraceptives.
- 4-Smoker patients or poor oral hygiene.

Data were analyzed using the statistical package for social sciences (SPSS, version 13).

Results

In this study 150 patients met the criteria of the selection of the patients they were divided into five groups. Each group contains equal numbers of males and females. The mean age of the patients was 21.5 years. The females were affected more than males in this study with 2.1: 1 ratio. The incidence of dry socket in the total number of the patients was 17.3% (table 1).The analysis of the data showed no significant relations between the five groups as the P value was > 0.05 (table 2).Most of the patients (52.24) developed dry socket in third day after tooth extraction (fig.1).

Discussion

Dry socket is the most common complication following a tooth extraction with a peak incidence in the 40-45 year old age group⁽⁸⁾ . Most studies state that

the incidence of dry socket is 1%-30% for mandibular third molars. The results of this study were in agreement with other reports^(9,10). In this study the females affected more than males and the difference in the occurrence of dry socket between males and females was statistically insignificant between all the groups which is similar to the findings of other studies^(11,12). The prevention of dry socket has in the past involved both pharmacologic and surgical approaches. Pharmacologic methods used in the prevention of dry socket have included use of antibiotic preparations placed in to the socket after extraction and antiseptic rinses. However, a number of authors recommend that the use of systemic antibiotics isn't necessary in non immunocompromised patients unless there are symptoms of malaise and lymphadenopathy. They recommend that the use of antibiotics in the extractions socket be reserved for those with history of previous dry sockets or for immunocompromised patients^(1,13). In our study the use of antibiotics would not affects the incidence of dry socket compared with other group which not used antibiotics. Rango showed 50% reduction in dry socket in patients who were rinsed for 30 s with a 0.12% Chlorhexidine gluconate solution⁽¹⁴⁾. Also other study founded a 38% reduction in the incidence of dry socket in patients who rinsed with 15 ml 0.12% Chlorhexidine gluconate for one week before and one week after the extraction, with no side effects due to chlorhexidine use⁽¹⁵⁾. The finding in this study showed no effects of the use of post operative chlorhexidine in the development of dry socket. In a normal post extraction socket,

thrombin and fibrinogen together form a fibrin clot over which epithelium migrates. Several theories have been presented on the a etiology of dry socket. They include; bacterial infections, trauma, and biochemical agents. The increased fibinolytic activity and activation of plasminogen to plasmin in the presence of tissue activators in dry socket is thought to be affects the integrity of post extraction blood clot⁽¹⁶⁾. From the mentioned above findings the causes of dry socket can be attributed to three major factors. First the condition of the tooth and its periodontal tissues before tooth extraction. The condition of pericoronitis is the important factor in development of infection of the alveolar bone which needs to be considered preoperatively. The second factor is the surgical technique used. Trauma result in compression of the bone lining the socket as well as possible thrombosis of the underlying vessels, reducing blood perfusion. Some associate trauma with a reduction in tissue resistance & consequently wound infection by anaerobes⁽¹⁰⁾. Birn found the relates damage to cells & alveolar bone to release of tissue activators of fibrinolytic activity [factor XII or Hageman factor, urokinase from blood, tissue, & endothelial plasmonigin activators] which affects the integrity of the blood clot⁽⁴⁾. While the third factor which affects the development of dry socket is the general condition of the patients including age, sex, smoking, medical condition and history of drugs administration. The use of different drugs postoperative in this study showed no differences in the incidence of dry socket which high lighten the use of preventive measures to decrease the occurrences of such condition.

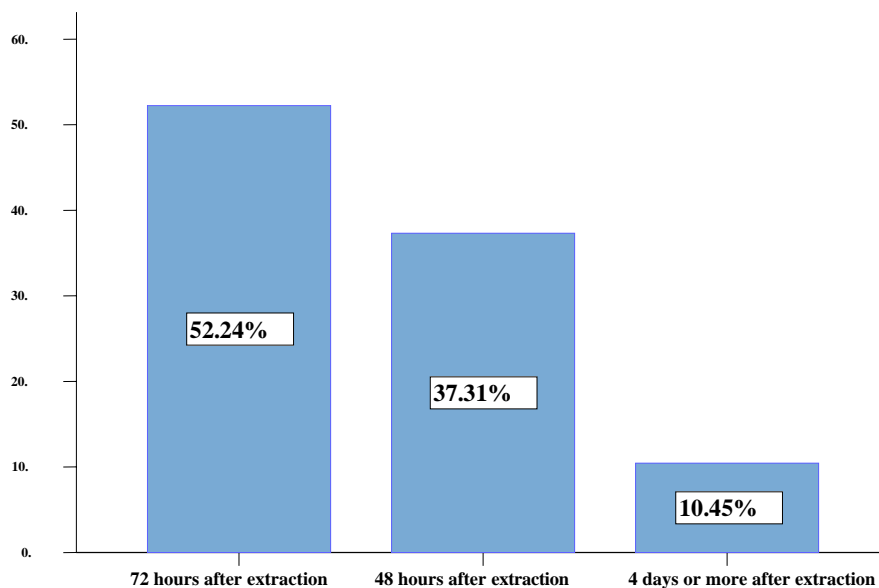


Fig.(1):- Bar chart showed the time of dry socket development.

Table (1):- Distribution of dry socket according to the sex in all groups.

Sex	DS(+ve)*	%	DS(-ve)	%
Male	8	5.3	67	44.6
Female	18	12	57	38
Total	26	17.3	124	82.6

DS* : Dry socket

Table (2):- Analysis of groups according to the incidence of dry socket.

Group		Dry socket		P-value
		No	Yes	
Group A	Female	15	4	0.199
	Male	15	2	
Group B	Female	15	3	0.286
	Male	15	1	
Group C	Female	15	3	0.343
	Male	15	2	
Group D	Female	15	4	0.283
	Male	15	2	
Group E	Female	15	4	0.269
	Male	15	1	

References

- 1-Lilly GE, Osbon DB, Rael EM, Samuels HS, Jones JC. Alveolar osteitis associated with mandibular third molar extractions. *JADA* 1974; 88:802-6.
- 2-Bloomer CR. Alveolar osteitis prevention by immediate placement of medicated packing. *Oral Surg Oral Med Oral Pathol Oral Radiol Endod* 2000; 90: 282-284.
- 3-Al-Khateeb T.H, Bataineh A.B. Pathology Associated With Impacted Mandibular Third Molars in a Group of Jordanians. *J Oral Maxillofac Surg* 2006; 64:1598-1602.
- 4-Birn H. Etiology and pathogenesis of fibrinolytic alveolitis („dry socket“). *Int J Oral Surg* 1973; 2:215-263.
- 5-Fazakerley M, Field EA. Dry socket: A painful post-extraction complication (a review). *Dent Update* 1991; 18:31-4.
- 6-Krekmanov L, Nordenham A. Post-operative complications after surgical removal of mandibular third molars. *Int J Oral Maxillofac Surg* 1986;15:25-9.
- 7-Krekmanov L. Alveolitis after operative removal of third molar in the mandible. *Int J Oral Surg* 1981; 10: 173-179.
- 8-Rood JP, Danford M. Metronidazole in the treatment of dry socket. *Int J Oral Surg* 1981; 10:345-7.
- 9-Turner PS. A clinical study of “dry socket.” *Int J Oral Surg* 1982;11:226-31.
- 10-Blum IR. Contemporary views on dry socket (alveolar osteitis): a clinical appraisal of standardization, aetiopathogenesis and management: a critical review. *Int J Oral Maxillofac Surg.* 2002; 31: 309-317.
- 11-Garcia AG, Grana PM, Sampedro FG, Diago MP, Rey JM. Does oral contraceptive use affect the incidence of complications after extraction of a mandibular third molar? *Br Dent J* 2003; 194:453-5.
- 12-Jaffar N, Nor GM. The prevalence of post-extraction complications in an outpatient dental clinic in Kuala Lumpur Malaysia – a retrospective survey. *Singapore Dent J* 2000; 23(1): 24-28.
- 13-Goldman DR, Kilgore DS, Panzer JD, Atkinson WH. Prevention of dry socket by local application of Lincomycin in Gelfoam. *Oral Surg Oral Med Oral Pathol Oral Radiol Endod* 1973; 35:472-4.
- 14-Rango JR, Szkutnik AJ. Evaluation of 0.12% chlorhexidine rinse on the prevention of alveolarosteitis. *Oral Surg Oral Med Oral Pathol Oral Radiol Endod* 1991; 72:524-6.
- 15-Hermesch CB, Milton TJ, Biesbrock AR. Perioperative use of 0.12% chlorexidine gluconate for the prevention of alveolar osteitis. *Oral Surg Oral Med Oral Pathol Oral Radiol Endod* 1998; 85:381-7.
- 16-Awang MN. The aetiology of dry socket: a review. *Int Dent J* 1989; 39:236-40.